



PRESENTING CLINICAL SIGNS

DATE History: Loud murmur.

11/28/22

ECHOCARDIOGRAPHIC FINDINGS

2D, M-mode, and Doppler study.

PERFORMED BY:

Kelly Vazquez

There is moderate to severe left atrial dilation. The mitral valve leaflets are thickened and exhibit systolic prolapse. A moderate to severe jet of eccentric mitral regurgitation is present. There is moderate to severe left ventricular dilation. Left ventricular systolic function is normal. The aorta and aortic valve are normal. Right atrial and right ventricular dimensions are normal. The tricuspid valve leaflets are mildly thickened, and a mild jet of tricuspid regurgitation is present. The pulmonary artery and pulmonic valve are normal. No shunting lesions are visualized. No pericardial effusion or cardiac masses are seen.

INTERPRETED BY

Keith Blass, DVM,
MS, DACVIM
(Cardiology)

PATIENT

Tyson Angolo

LA - 36.3 mm
LVIDd - 36.9 mm
LVIDs - 22.4 mm
FS - 39%
RA - 16.1 mm
LVOT - 1.01 m/s
RVOT - 0.79 m/s

SPECIES

Canine

ASSESSMENT/RECOMMENDATIONS

Degenerative mitral and tricuspid valve disease

BREED

Havanese

This examination demonstrates regurgitation of blood across Tyson's mitral and tricuspid valves resulting from degenerative valve disease. Tyson's tricuspid valve disease is mild, and appears to be well-compensated at this time. His mitral valve disease is significantly more advanced, as Tyson has moderate to severe mitral regurgitation present, with moderate to severe secondary dilation of both his left atrium and left ventricle. Given the severity of his disease, Tyson is at high risk for the development of clinical signs, such as coughing, exercise intolerance, syncope, and labored breathing, therefore, careful monitoring for these signs is recommended.

SEX

MN

I recommend starting Tyson on pimobendan (2.5 mg am, 1.25 mg pm), as this medication should help to slow the progression of his mitral valve disease.

AGE

11 y

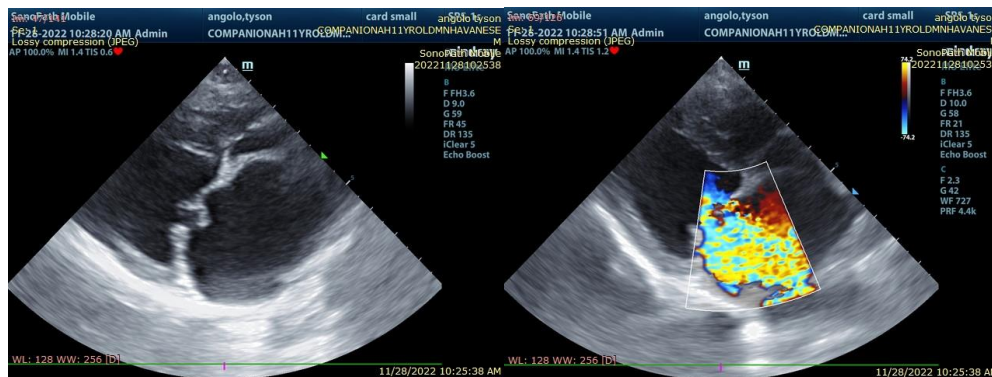
A recheck echocardiogram is recommended in 6-9 months. Thoracic radiographs are recommended if Tyson experiences respiratory clinical signs.

WEIGHT

14 lb

HOSPITAL NAME

Companion AH
Parsippany



REFERRING VET

Dr. Tsai



DATE

11/28/22

The information and recommendations provided are based on the images presented by the referring veterinarian. No evaluation can be communicated regarding pathology that was not visible in the image/video clips provided.

PERFORMED BY:

Kelly Vazquez

Thank you for this referral. If the clinical or image interpretation does not parallel your findings or if I can be of any further assistance please contact me.

INTERPRETED BY

Keith Blass, DVM,
MS, DACVIM
(Cardiology)

Keith Blass, DVM, MS, DACVIM (Cardiology)
KeithBlass@gmail.com
631-804-5754

PATIENT

Tyson Angolo

SPECIES

Canine

BREED

Havanese

SEX

MN

AGE

11 y

WEIGHT

14 lb

HOSPITAL NAME

Companion AH
Parsippany

REFERRING VET

Dr. Tsai